J Neurosurg 91:384–390, 1999

Correlation of the relationships of brain–tumor interfaces, magnetic resonance imaging, and angiographic findings to predict cleavage of meningiomas

FARUK İLDAN, M.D., METIN TUNA, M.D., ALP İSKENDER GÖÇER, M.D., BÜLENT BOYAR, M.D., HÜSEYIN BAĞDATOĞLU, M.D., ORHAN ŞEN, M.D., SEBAHATTIN HACIYAKUPOĞLU, M.D., AND H. REFIK BURGUT, PH.D.

Department of Neurosurgery, Çukurova University School of Medicine, Balcalı–Adana, Turkey

Object. The authors examined the relationships of brain–tumor interfaces, specific magnetic resonance (MR) imaging features, and angiographic findings in meningiomas to predict tumor cleavage and difficulty of resection.

Methods. Magnetic resonance imaging studies, angiographic data, operative reports, clinical data, and histopathological findings were examined retrospectively in this series, which included 126 patients with intracranial meningiomas who underwent operations in which microsurgical techniques were used. The authors have identified three kinds of brain–tumor interfaces characterized by various difficulties in microsurgical dissection: smooth type, intermediate type, and invasive type. The signal intensity on T_1-weighted MR images was very similar regardless of the type of brain–tumor interface ($p > 0.1$). However, on T_2-weighted images the different interfaces seemed to correlate very precisely with the signal intensity and the amount of peritumoral edema ($p < 0.01$), allowing the prediction of microsurgical effort required during surgery. On angiographic studies, the pial–cortical arterial supply was seen to participate almost equally with the meningeal–dural arterial supply in vascularizing the tumor in 57.9% of patients. Meningiomas demonstrating hypervascularization on angiography, particularly those fed by the pial–cortical arteries, exhibited significantly more severe edema compared with those supplied only from meningeal arteries ($p < 0.01$). Indeed, a positive correlation was found between the vascular supply from pial–cortical arteries and the type of cleavage ($p < 0.05$).

Conclusions. In this analysis the authors proved that there is a strong correlation between the amount of peritumoral edema, hyperintensity of the tumor on T_2-weighted images, cortical penetration, vascular supply from pial–cortical arteries, and cleavage of the meningioma. Therefore, the consequent difficulty of microsurgical dissection can be predicted preoperatively by analyzing MR imaging and angiographic studies.

KEY WORDS • meningioma • magnetic resonance imaging • angiography • brain–tumor interface

ALTHOUGH intracranial meningiomas traditionally have been regarded as encapsulated and curable tumors, recurrence of these lesions has been reported in 10 to 32% of cases, even after complete resection.[1,25] The recurrent tumors as well as the remnants of subtotal resections usually grow slowly.[12,17] The prognosis for patients with meningiomas depends on many parameters, including the preoperative condition of the patient, the location and size of the meningioma, the extent of tumor removal, the histological composition of the tumor, and the effect of various therapeutic modalities.[3,5,20] The most obvious reason for tumor recurrence is the primary failure of complete microsurgical excision of the lesion. Although one of the most important factors in predicting the surgical outcome could be the degree of tumor cleavage, it has not been reported extensively in the literature to date. Three preoperative modalities exist to assist in the prediction of the degree of tumor cleavage: magnetic resonance (MR) imaging, computerized tomography (CT) scanning, and angiography. Sindou and Alaywan[30] have postulated that "cleavability" can be predicted from preoperative angiographic studies. The MR appearance of intracranial meningioma and its usefulness in assessing extracerebral tumor location, vascularity, arterial encasement, and venous sinus invasion have been the subject of several articles.[21,31,36] However, the prognostic value of MR imaging for predicting the degree of cleavage in meningiomas has not yet been reported in the literature. Therefore, we have analyzed the actual dissecting plane between the meningioma and the underlying cortex and the predictability of cleavage based on preoperative MR imaging and angiographic findings. In this article, we report the use of MR imaging and angiographic studies to predict meningioma cleavage, an evaluation that will consequently affect the surgical plan and ease the surgical approach.

Clinical Material and Methods

Patient Population

Between 1989 and 1998, 176 patients underwent treatment for intracranial meningiomas at our neurosurgical department; in 126 of them sufficient data were available

for analysis. Medical charts and neuroradiographic studies obtained in all patients with verified meningiomas were analyzed with respect to clinical, radiographic, operative, and pathological data. Information regarding the 126 patients was obtained retrospectively by three neurosurgeons (B.B., A.I.G., M.T.) who reviewed these patients' records and recorded their findings on follow-up examination. All radiographic studies, including MR images and selective bilateral (and if necessary vertebral) external–internal carotid artery angiograms obtained using the transfemoral arterial technique (in 76 cases), were reevaluated in a blinded fashion by three other neurosurgeons (F.I., S.H., H.B.) to support and expand the original reports.

Neuroradiographic Imaging and Intensity Scoring

Readers scored the visible signal intensity of each meningioma relative to that of the cortical gray matter on a scale of 1 to 5 for T_1- and T_2-weighted MR images (Table 1). Fractional scores were not allowed. Unrefined scoring data on MR images and unrefined grading data on angiographic studies were collected and analyzed to detect any significant variance. Signal intensity scores were consistent among all three readers. When there were variations in scoring of MR images or grading of angiographic studies, the final decision was made according to the majority of the readers. All patients chosen for this study had not previously undergone operation or radiotherapy. The most recent preoperative MR image was used for scoring.

Most of the MR imaging was performed using a 1.5-tesla imager (General Electric, Milwaukee, WI). Precontrast T_1-weighted MR images (TR 600 to 800 msec, TE 20 msec, and 1–2 excitations) and T_2-weighted images (TR 2800 msec, TE 90 msec, and 1 excitation) were obtained. In general, sections were 5 mm thick with a 2.5-mm interval between them. Gadolinium (Gd)-diethylenetriamine pentaacetic acid (DTPA) contrast material (0.1 mmol/kg) was used in 84 cases. The T_1-weighted images were obtained in various planes depending on the location of the tumor. Tumors located along the falx and convexity were imaged in the cortical and axial planes, and tumors at the base of the skull were generally imaged in the sagittal and coronal planes. The MR images were analyzed retrospectively with the readers knowing that the lesions were all meningiomas but not knowing their histological subtypes. Lesion locations were noted in eight groups, and size was noted in four groups on MR images.

Criteria used for scoring are shown in Table 1.[11] If there were two distinct tumor components that had different signal intensities, the intensity of the larger component was scored. Heterogeneity of the intensity pattern related to calcification, cyst formation, vascularity, inherent speckling, or mottling was noted in each case. The other characteristics that probably were also indicative of the degree of tumor cleavage included the cerebrospinal fluid (CSF) cleft, arterial encasement, pial vascular rim, and the integrity of the cerebral or cerebellar cortical layer surrounding the tumor; these were noted in each case as well. The amount of peritumoral edema was evaluated using a four-point scale based on its spatial extension and degree of hyperdensity on T_2-weighted images (0, absence of edema; 1, marginal edema; 2, evident edema; 3, severe edema).

TABLE 1

Visual scoring system for meningioma signal intensity on MR imaging

Score	Features
T_1-weighted images	
1	markedly hypointense to gray matter, nearly as dark as CSF
2	mildly hypointense to gray matter but easily distinguished from it
3	nearly isointense w/ cortical gray matter, may be difficult to separate
4	mildly hyperintense to gray matter, but easily distinguished
5	markedly hyperintense to gray matter, nearly as bright as fat
T_2-weighted images	
1	markedly hypointense to gray matter, nearly as dark as cortical bone
2	mildly hypointense to gray matter but easily distinguished from it
3	nearly isointense w/ cortical gray matter, may be difficult to separate
4	mildly hyperintense to gray matter, but easily distinguished
5	markedly hyperintense to gray matter, nearly as bright as CSF

Arterial Supply Categories

All angiograms were reevaluated in detail, with careful description of the dural and cortical arterial supply to the lesion. On the basis of the findings on selective angiographic studies in 76 cases, we classified these tumors into three groups. In the first (Group A), tumors stained with dye were fed mainly by the dural arterial supply and those not stained were fed by the pial–cortical arterial supply. In the second (Group B), the pial–cortical arterial supply was seen to participate in less than equal amounts with the meningeal–dural supply. In the third (Group C), the pial–cortical arterial supply was seen to participate in at least equal amounts with the meningeal–dural supply. The cases in which we used preoperative embolization were not included in this study.

Microsurgical Techniques and Tumor Types

We used classic microsurgical dissection techniques and equipment, including an operative microscope, microinstruments, and bipolar forceps. The cases in which we used a laser or ultrasonic aspirator were not included in the series. Gross observation of the tumor consistency, venous sinus involvement, and tumor vascularity, as well as dissection features including degree of cleavage and definition of subpial and extrapial planes were evaluated from the operative report. We have graded the interfaces according to the microsurgical observations, as follows.

Type I. Smooth type: the tumor was dissected easily from the brain by using an extraarachnoidal route. Subarachnoid space was preserved in these cases.

Type II. Intermediate type: the arachnoid membrane was extremely thin and adherent to the tumor. Entrapped vessels were seen between the brain tissue and the tumor.

Type III. Invasive type: pial membrane was adherent to the tumor in some areas, and precise microsurgical dissection was nearly impossible in more than one third of the brain–tumor interface on the extrapial route. It was necessary to operate subpially for microsurgical dissection in these areas. Crossing vessels were present between the brain tissue and the tumor.

Histological Subtypes

The tumors were classified into their predominant his-

TABLE 2
Location of meningiomas in 126 patients

Location	No. of Patients (%)
convexity	33 (26.1)
parasagittal &/or parafalcine	30 (24.4)
planum sphenoidale	16 (12.7)
sphenoid wing	21 (16.6)
parasellar	10 (7.9)
posterior fossa	11 (8.7)
other	5 (3.9)

tological subtypes according to the scheme of Russell and Rubinstein,[26] as meningothelial (syncytial), fibroblastic, transitional, and angioblastic. If there were mitotic figures, tumor infiltration into the surrounding brain tissue, nuclear atypia or necrosis, or poor differentiation, the tumors were classified as atypical or malignant.[2] Additionally, calcification, fibrosis, hemorrhage, and vascularity of the tumor were noted as present or absent.

Statistical Analysis

Variables from either MR imaging or angiographic studies were classified by cleavage types. Association was then assessed using the chi-square test and a significance level of 0.05 was assigned. To determine the significant variables from MR imaging and/or angiographic studies in predicting correct classification of the cleavage type, multivariate logistic regression on ordinal data was used. Variables were entered either simultaneously or in a stepwise manner. Of the terms used, concordance implies correct classification of tumors into cleavage types with corresponding values on significant variables, discordance implies incorrect classification of cleavage types; tied implies that no decision could be made based on the logistic regression model with the ordinal response variable.

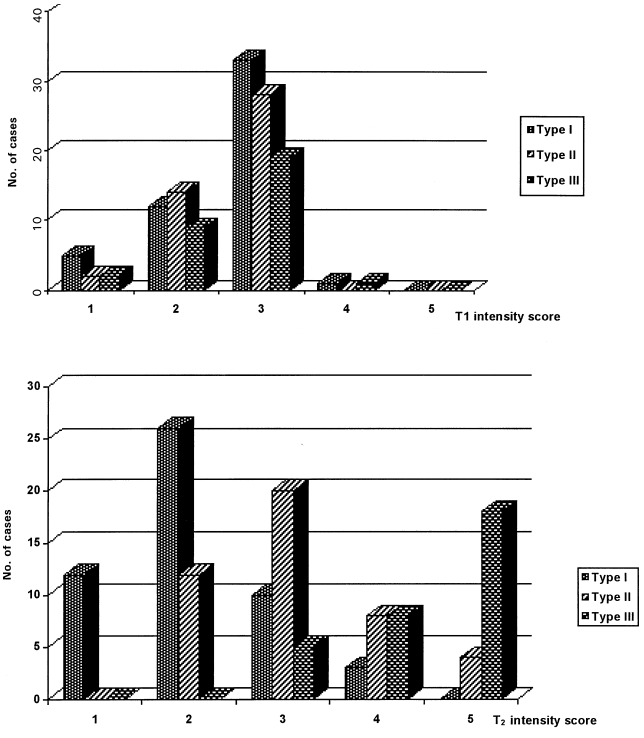

FIG. 1. Bar graphs showing relationship between Gd-DTPA intensity scores and tumor cleavage types. *Upper:* Intensity scores on T_1-weighted MR imaging ($p > 0.1$). *Lower:* Intensity scores on T_2-weighted MR imaging ($p < 0.01$).

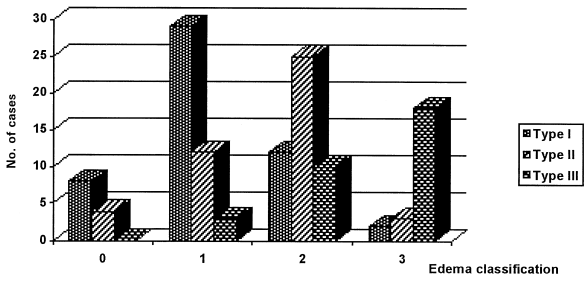

FIG. 2. Bar graph showing relationship between edema and tumor cleavage types. The tumors with moderate and severe edema tended to be Types II and III, respectively ($p < 0.01$).

Results

The patients studied included 59 men and 67 women whose ages ranged between 19 and 79 years (average ± standard error, 56.7 ± 1.8 years). Convexity meningiomas were the most common, followed by tumors in the parasagittal and/or parafalcine areas. Table 2 lists the location of the meningiomas. The tumor size was classified into the following groups; smaller than 3 cm in diameter in 20 cases (15.9%); 3 to 6 cm in 73 cases (57.9%); 6 to 9 cm in 22 cases (17.4%); and larger than 9 cm in 11 cases (8.8%). The quality of survival was evaluated both pre- and postoperatively according to the Karnofsky Performance Scale (KPS).[22] The preoperative KPS scores ranged from 40 to 90 in our series, and 24 patients failed to achieve a KPS score of 70 preoperatively.

Magnetic resonance images obtained without Gd contrast material demonstrated all but four meningiomas clearly. The tumors in these cases were small and poorly defined on the MR images and were clearly recognized only in the images in which Gd-DTPA contrast was used. In the patients who had intensely calcified tumors (four cases), the signal intensity of the soft-tissue fraction only was assessed. On T_1-weighted images, 63.5% of the tumors (80 cases) were nearly isointense with cortical gray matter. Most of the remaining tumors (34.9%; 44 cases) showed moderate to marked hypointensity, and two (1.6%) showed high signal intensity on T_1-weighted images. As seen in Fig. 1 *upper*, tumor signals on T_1-weighted MR images were very similar regardless of different brain–tumor interfaces ($p > 0.1$). A heterogeneous intensity pattern was related to many factors, including cyst formation, calcification, and tumor vascularity, and an inherent speckling or mottling was present in 103 cases (81.7%) in our series that was better evaluated on T_2-weighted images. Correlation of signal intensity with cleavage types on T_2-weighted images proved that the type of cleavage was significantly correlated with T_2 intensity scores, as seen in Fig. 1 *lower*. In 32.5% of cases, bright tumors (scored 4–5) correlated with the Type III brain–tumor interface (invasive type). In 27.7% of cases,

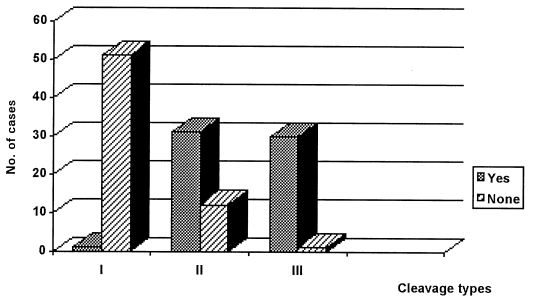

FIG. 3. Bar graph showing relationship between cortical penetration and tumor cleavage types ($p < 0.01$).

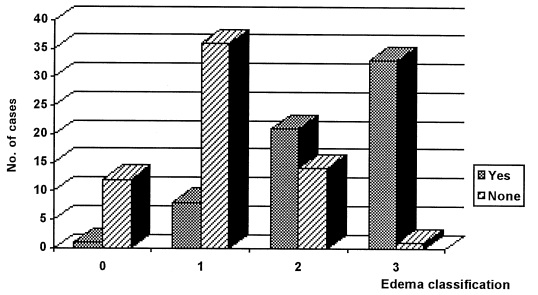

FIG. 4. Bar graph showing relationship between peritumoral edema and cortical penetration by the lesion ($p < 0.01$).

mildly isodense tumors (scored 3) correlated with the Type II interface (intermediate type). In 39.6% of cases, tumors that were dark on T_2-weighted images (scored 1–2) correlated strongly with the Type I interface (smooth type) ($p < 0.01$). Because the tumor signal intensity on T_2-weighted MR images was found to correlate with the brain–tumor interface type, it provided some predictive value for degree of cleavage.

After obtaining these positive results we directed our attention to the amount of peritumoral edema and cortical penetration. The type of brain–tumor interface was found to be significantly correlated with the amount of edema seen on T_2-weighted MR images ($p < 0.01$). The tumors with the most severe edema tended to be in Types II and III (Fig. 2). Cortical penetration was found to be the most important parameter predicting the type of interface ($p < 0.01$, Fig. 3). On the other hand, the amount of peritumoral edema on T_2-weighted MR images was correlated with the presence of cortical penetration ($p < 0.01$, Fig. 4).

Gadolinium-DTPA contrast material was used in 66.6% of our patients (84 cases) in this series; Gd-DTPA–enhanced images provided additional information in delineating the tumor extent, particularly those located at the skull base. We found no relationship between the degree of contrast enhancement on T_1-weighted MR images and the degree of cleavage (data not shown). Also, no relationship was found between the presence of CSF cleft, cyst, arterial encasement, or venous sinus invasion and cleavage types (data not shown).

According to the findings on the selective angiographic studies there were 32 cases (42.1%) classified in Group A, 26 (34.2%) in Group B, and 18 (23.7%) in Group C. Although all three angiographic patterns were found in all three cleavage types, the type of cleavage was found to be correlated with the type of arterial supply ($p < 0.05$, Fig. 5). On the other hand, we have correlated angiographic groups with signal intensity and edema on T_2-weighted MR images. There was a significant correlation between the angiographic groups and peritumoral edema ($p < 0.01$); Groups B and C tended to be composed of the tumors with the most severe edema (scored as 3; Fig. 6). There was also a significant correlation between the angiographic groups and intensity scores on T_2-weighted MR images ($p < 0.01$). Groups A and B tended to include patients with scores of 1 to 2 and 3, whereas Group C tended to be composed of patients with scores of 4 to 5 (Fig. 7).

From multivariate analysis in which the only variables from MR studies included T_2-weighted intensity scores, edema, and cortical penetration, the concordance rate was found to be 93.4%, the discordance rate was 2.2%, and the tie rate was 4.4%. Cortical penetration and T_2 intensity scores were the most important variables in prediction. Furthermore, when the variables from angiographic studies in addition to those from MR images were included in the multivariate model, the concordance rate was found to be 94.1%, the discordance rate was 1.7%, and the tie rate was 4.1%.

The extent of tumor removal was graded according to the criteria of Simpson.[29] Complete tumor excision was achieved macroscopically in 102 cases (80.9%), with excision of its dural attachment. There were 10 tumors (7.9%) classified as Grade II in which only unipolar coagulation of the dural attachment was accomplished. Complete tumor excision without resection or coagulation of dural attachments in Grade III and subtotal removal in Grade IV was achieved in eight cases (6.3%), and decompression was achieved in Grade V in six cases (4.7%). According to the data from the operative reports, there were 51 Type I brain–tumor interfaces (smooth type), 44 Type II (intermediate type), and 31 Type III (invasive type). The tumor was easily dissected from the adjacent parenchyma via the extraarachnoidal route in cases with Type I interfaces (40.4%). Although microsurgical dissection was difficult, it was still possible in Type II (34.9%). Because of disruption of the cortical layer and pia adherent to the tumor in some areas, microsurgical dissection was nearly impossible in Type III (24.6%) via an exclusively extrapial route. Subpial dissection was necessary in some areas in tumors with this type of interface.

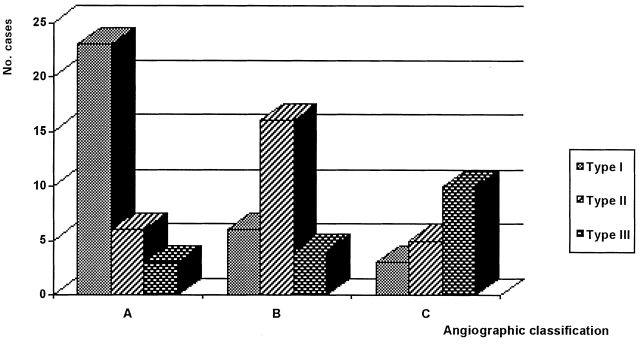

FIG. 5. Bar graph showing relationship between the angiographic group and tumor cleavage types ($p < 0.01$).

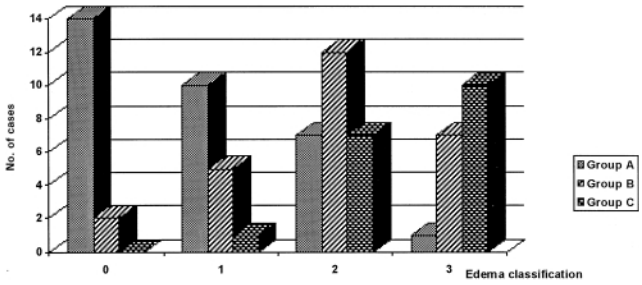

FIG. 6. Bar graph showing relationship between the angiographic group and edema ($p < 0.01$). Groups B and C in the angiographic classification tended to be identified in the tumors with severe edema (classified as Grade 3).

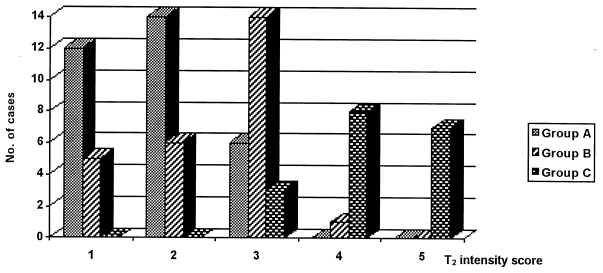

FIG. 7. Bar graph showing relationship between angiographic group and intensity scores on T_2-weighted MR imaging ($p < 0.01$).

We could find no correlation between histopathological features of the tumor and its signal intensity on T_1-weighted MR images ($p > 0.1$, data not shown). However, on T_2-weighted MR images, meningothelial meningiomas included a higher percentage of tumors that were hyperintense (scored 5). Fibroblastic and transitional meningiomas tended to be hypointense (scored 1–2) and isointense (scored 3) relative to gray matter ($p < 0.05$, data not shown). Atypical and angioblastic meningiomas were hyperintense on T_2-weighted MR images relative to gray matter. The distribution of meningiomas by histological subtype is shown in Table 3.

The quality of patient survival was assessed both pre- and postoperatively and graded according to the KPS. There were 12 deaths during the first 60 postoperative days for a 9.5% mortality rate. All of these patients suffered from huge meningiomas (> 6 cm in diameter) and had been in poor preoperative clinical condition. An obviously longer period of good quality survival was noted for the patients with small meningiomas. A KPS score of more than 80 of a possible 100 was obtained in 98 cases (77.7%). Tumor recurrence was found in 18 cases (14.2%) during a follow-up period ranging from 1 to 9 years (average 5.5 years).

Discussion

Although improvements such as developing surgical techniques, intraoperative microscopy, evoked potential monitoring, and better understanding of skull base anatomy have allowed meningioma resections to yield more favorable results, the management of these tumors remains a major challenge for neurosurgeons. Even though the treatment of choice in most cases is total resection, in some situations it is not possible without an unacceptable risk of morbidity.[10,25] Important factors that determine the success of total surgical removal include tumor location, size, and histological features, vascular and neural involvement, and patient age and general condition. Numerous reports that include all these parameters as prognostic factors of patient survival have been published with documentation of long follow-up experience.[5,23,34] However, the ability to predict the degree of meningioma cleavage has received little attention in the literature so far.[27,30]

Magnetic resonance imaging with Gd enhancement is the gold standard procedure for the diagnosis of meningiomas.[6,15,33] Magnetic resonance imaging signal intensity characteristics of meningiomas are useful adjuncts in presurgical characterization and they include cystic degeneration, consistency, vascularity, and histopathological features of the tumor. Despite considerable advances in imaging procedures, predicting the degree of tumor cleavage, which could be helpful in microsurgical dissection, is still a challenge for neurosurgeons. Although there has only been one report[30] in which a positive correlation was shown between evaluation of "cleavability" and vascular supply from the intrinsic cerebral arteries and meningeal circulation, there has been no report on the correlation between the prediction of the degree of tumor cleavage and MR findings. We present the first article in which the relationship between the degree of tumor cleavage and the tumor's MR imaging characteristics are evaluated in meningiomas.

Although an article describing the relationship between MR signal intensity and meningioma characterization was first published by Elster, et al.,[11] considerable controversy persists regarding the nature and predictability of signal change.[9] Hyperintense signal on T_2-weighted MR images is considered a multifactorial process and is correlated with tumor consistency and vascularity indicating a higher water content.[35] Subtype-specific intensity differences are attributed to the collagen distribution and tumor cell packing. Recently, Chen, et al.,[8] and Kaplan, et al.,[21] found a correlation between the MR signal intensities and the histopathological features of the tumors. The signal intensity of meningiomas on T_2-weighted MR images is considered to be a predictor of histological type. If the tumor is composed primarily of fibrous or transitional elements it is significantly hypointense on T_2-weighted MR images. On the other hand if the tumor is composed primarily of syncytial or angioblastic elements it is significantly hyperintense on T_2-weighted MR images. In our series we also found this correlation between the MR signal intensities and the histopathological features, which confirmed the results of Chen, et al.,[8] and Kaplan, et al.[21] However, although tumor signals were very similar on T_1-weighted MR images regardless of different brain–tumor interfaces, tumor signal intensity on T_2-weighted MR images was found to correlate and offer some predictive value for the degree of cleavage of meningiomas. A significant positive correlation was found between the tumor signal intensity score on T_2-weighted MR images and the specific types of brain–tumor interface in our series. The signal intensity score on T_2-weighted MR images proved to be very important in determining the degree of cleavage of the meningioma. However, despite the recent rapid proliferation

of literature on this modality, no MR imaging–based series in which this correlation has been explored has been published to date. In our series we found that correct characterization of the subtype of brain–tumor interface based on the signal changes on T_2-weighted MR images was possible in the majority of cases.

Meningiomas are well-encapsulated intracranial tumors. They are initially separated from the cerebral white matter, in which vasogenic edema tends to accumulate, by arachnoid membrane, the subarachnoid space, the pia mater, and the cerebral cortex. Arachnoid membrane is impervious to fluid as part of the blood-CSF barrier. The pia mater is easily permeable to water and electrolytes but not so much to macromolecular substances, including the proteins of vasogenic edema fluid. It has also been proven that cerebral cortex is quite resistant to the spread of vasogenic edema fluid because of its tightly interwoven cellular structure.[13] The disruption of these barriers in large meningiomas supports the theory that this factor is related at least in part to the genesis of edema. Although many factors have been suggested individually as possible mechanisms for peritumoral edema, including tumor size, location, histological features, mechanical compression of a draining vein, disruption of the cortical layer, and secretory activity by tumor cells,[14] the cause of peritumoral edema associated with meningioma is most likely multifactorial.[4,16,21,22] Go, et al.,[14] have reported a significant correlation between the disruption of cerebral cortex and the severity of edema. These data were confirmed by Salpietro, et al.,[27] in their report on a series of 52 intracranial meningiomas. They pointed out that there was a positive correlation between the grade of peritumoral edema and the degree of cortical penetration. We also observed this correlation in our series. The data obtained in our series strongly correlate with and confirm the CT analyses performed by Salpietro, et al.,[27] and Go, et al.[14] Our analysis indicated that there was a statistical relationship between the severity of the subcortical peritumoral edema and the breach of the cerebral or cerebellar cortex by meningioma on one hand and the degree of tumor cleavage on the other.

Meningiomas continue to recur even when complete excision is accomplished. Jellinger and Slowik[19] compared recurrent with nonrecurrent meningiomas after complete excision. They stated that increased cellularity and increased mitotic rates were more frequent in the recurring group but that many nonrecurrent tumors also exhibited these features to some degree. The most obvious reason for tumor recurrence can be attributed mainly to two factors. One of these is the failure to evaluate the extent of the meningioma during the surgery. The other is the involvement of vital neurovascular structures. Although the use of MR imaging with Gd-DTPA enhancement better outlines the true size and shape of the meningioma, failure to evaluate the extent of the meningioma during surgery because of the invasive cleavage may cause residual tumor margins despite the fact that the surgeon's assessment was that the tumor had been completely removed.[24] Aside from the problem of involvement of adjacent critical vascular or neural structures, invasive cleavage limits complete microscopically aided resection. On the other hand, invasive cleavage may be responsible for serious disability after complete removal of benign meningiomas, particularly in eloquent areas. Disability is also related to the size and vascularity of the lesion. The existence of pial–cortical blood supply to meningiomas and its association with poor patient outcomes have been well reported in connection with petroclival meningiomas by Sekhar, et al.,[28] and in meningiomas in the sensorimotor area by Sindou and Alaywan.[30] The dilemma lies in the need to predict the degree of cleavage preoperatively by using diagnostic procedures including MR imaging and angiographic studies.

TABLE 3

Histological subtypes of meningiomas in 126 patients

Subtypes	No. of Patients (%)
transitional	42 (33.3)
meningothelial	33 (26.1)
fibroblastic	24 (19.0)
angioblastic	21 (16.6)
atypical	6 (4.7)

Although pial–cortical arteries are clearly involved in all parenchymal brain tumors, they are less involved in the blood supply to the meningioma. This type of vascular supply may play a partial role in the occurrence of peritumoral edema. Challa, et al.,[7] and Stevens, et al.,[32] reported in separate articles on a positive correlation between the vascularity of the meningioma and the grade of peritumoral edema. Inamura, et al.,[18] first reported on a series of 35 patients in whom the vascular supply from the intrinsic cerebral arteries was a factor that affected peritumoral edema. They postulated that a peritumoral brain edema–producing substance, if present, might move into the brain parenchyma through the blood supply from the intrinsic cerebral arteries. In our study we found a strong correlation between the amount of peritumoral edema and the vascular supply from the pial–cortical arteries. On the other hand, Sindou and Alaywan[30] reported that vascular supply by pial arteries and the extension of peritumoral hypodensity on CT scans are the parameters to use to predict the difficulty in finding a smooth cleavable plane between the tumor and parenchyma. We have also confirmed this association in our series by observing the occurrence of extensive peritumoral edema when meningioma tissue received vascular supply from the intrinsic cerebral arteries.

Conclusions

Our analysis indicated that there was a strong statistical correlation among the amount of peritumoral edema, the degree of intensity of the tumor on T_2-weighted MR images, cortical penetration, vascular supply from pial–cortical arteries on angiographic studies, and the degree of meningioma cleavage. We postulated that, according to the density of the tumor, cortical penetration, the amount of peritumoral edema on MR images, and the participation of the pial–cortical arteries in the vascular supply of the tumor on angiographic studies, the degree of meningioma cleavage can be predicted preoperatively on the basis of MR and angiographic studies. We suggest that the degree of meningioma cleavage should be considered among the

many important factors including tumor location, anatomical structures involved, tumor size, and histological features in determining the success of surgery.

References

1. Adegbite AB, Khan MI, Paine KWE, et al: The recurrence of intracranial meningiomas after surgical treatment. **J Neurosurg 58:**51–56, 1983
2. Al-Mefty O (ed): **Meningiomas.** New York: Raven Press, 1991
3. Alvarez F, Roda JM, Romero MP, et al: Malignant and atypical meningiomas: a reappraisal of clinical, histological, and computed tomographic features. **Neurosurgery 20:**688–694, 1987
4. Benzel EC, Gelder FB: Correlation between sex hormone binding and peritumoral edema in intracranial meningiomas. **Neurosurgery 23:**169–174, 1988
5. Black PM: Meningiomas. **Neurosurgery 32:**643–657, 1993
6. Bydder GM, Kingsley DPE, Brown J, et al: MR imaging of meningiomas including studies with and without gadolinium-DTPA. **J Comput Assist Tomogr 9:**690–697, 1985
7. Challa VR, Moody DM, Marshall RB, et al: The vascular component in meningiomas associated with severe cerebral edema. **Neurosurgery 7:**363–368, 1980
8. Chen TC, Zee CS, Miller CA, et al: Magnetic resonance imaging and pathological correlates of meningiomas. **Neurosurgery 31:**1015–1022, 1992
9. Demaerel P, Wilms G, Lammens M, et al: Intracranial meningiomas: correlation between MR imaging and histology in fifty patients. **J Comput Assist Tomogr 15:**45–51, 1991
10. De Monte F: Current management of meningiomas. **Oncology (Huntingt) 9:**83–96, 1995
11. Elster AD, Challa VR, Gilbert TH, et al: Meningiomas: MR and histopathologic features. **Radiology 170:**857–862, 1989
12. Firsching RP, Fischer A, Peters R, et al: Growth rate of incidental meningiomas. **J Neurosurg 73:**545–547, 1990
13. Gazendam J, Go KG, van Zanten AK: Composition of isolated edema fluid in cold-induced edema. **J Neurosurg 51:**70–77, 1979
14. Go KG, Wilmink JT, Molenaar WM: Peritumoral brain edema associated with meningiomas. **Neurosurgery 23:**175–179, 1988
15. Haughton VM, Rimm AA, Czervionke LF, et al: Sensitivity of Gd-DTPA-enhanced MR imaging of benign extraaxial tumors. **Radiology 166:**829–833, 1988
16. Hino A, Imahori Y, Tenjin H, et al: Metabolic and hemodynamic aspects of peritumoral low-density areas in human brain tumor. **Neurosurgery 26:**615–621, 1990
17. Hoshino T, Nagashima T, Murovic JA, et al: Proliferative potential of human meningiomas of the brain. A cell kinetics study with bromodeoxyuridine. **Cancer 58:**1466–1472, 1986
18. Inamura T, Nishio S, Takeshita I, et al : Peritumoral brain edema in meningiomas—influence of vascular supply on its development. **Neurosurgery 31:**179–185, 1992
19. Jellinger K, Slowik F: Histological subtypes and prognostic problems in meningiomas. **J Neurol 208:**279–298, 1975
20. Kallio M, Sankila R, Hakulinen T, et al: Factors affecting operative and excess long-term mortality in 935 patients with intracranial meningioma. **Neurosurgery 31:**2–12, 1992
21. Kaplan RD, Coons S, Drayer BP, et al: MR characteristics of meningioma subtypes at 1.5 tesla. **J Comput Assist Tomogr 16:**366–371, 1992
22. Kawase T, Ohira T, Murakami H, et al: Influence of peritumoral edema on rCBF and on cerebral function: analysis by xenon-enhanced CT and EEG topography, in Inaba Y, Klatzo I, Spatz M (eds): **Brain Edema.** Berlin: Springer-Verlag, 1985, pp 484–489
23. Lunsford LD: Contemporary management of meningiomas: radiation therapy as an adjuvant and radiosurgery as an alternative to surgical removal? **J Neurosurg 80:**187–190, 1994
24. Maroon JC, Kennerdell JS, Vidorich DV, et al: Recurrent spheno-orbital meningioma. **J Neurosurg 80:**202–208, 1994
25. Mirimanoff RO, Dosoretz DE, Linggood RM, et al: Meningioma: analysis of recurrence and progression following neurosurgical resection. **J Neurosurg 62:**18–24, 1985
26. Russell DS, Rubinstein LJ: **Pathology of Tumours of the Nervous System, ed 5.** Baltimore: Williams & Wilkins, 1989, pp 449–507
27. Salpietro FM, Alafaci C, Lucerna S, et al: Peritumoral edema in meningiomas: microsurgical observations of different brain tumor interfaces related to computed tomography. **Neurosurgery 35:**638–642, 1994
28. Sekhar LN, Swamy NKS, Jaiswal V, et al: Surgical excision of meningiomas involving the clivus: preoperative and intraoperative features as predictors of postoperative functional deterioration. **J Neurosurg 81:**860–868, 1994
29. Simpson D: The recurrence of intracranial meningiomas after surgical treatment. **J Neurol Neurosurg Psychiatry 20:**22–39, 1957
30. Sindou MP, Alaywan M: Most intracranial meningiomas are not cleavable tumors: anatomic-surgical evidence and angiographic predictability. **Neurosurgery 42:**476–480, 1998
31. Spagnoli MV, Goldberg MI, Grossman RI, et al: Intracranial meningiomas: high-field MR imaging. **Radiology 161:** 369–375, 1986
32. Stevens JM, Ruiz JS, Kendall BE: Observations on peritumoural oedema in meningioma. Part II. Mechanisms of oedema production. **Neuroradiology 25:**125–131, 1983
33. Watabe T, Azuma T: T1 and T2 measurements of meningiomas and neuromas before and after Gd-DTPA. **AJNR 10:**463–470, 1989
34. Wilson CB: Meningiomas: genetics malignancy, and the role of radiation in induction and treatment. The Richard C. Schneider Lecture. **J Neurosurg 81:**666–675, 1994
35. Yamaguchi N, Kawase T, Sagoh M, et al: Prediction of consistency of meningiomas with preoperative magnetic resonance imaging. **Surg Neurol 48:**579–583, 1997
36. Zimmerman RD, Fleming CA, Saint-Louis LA, et al: Magnetic resonance imaging of meningiomas. **AJNR 6:**149–157, 1985

Manuscript received November 2, 1998.
Accepted in final form April 30, 1999.

Address reprint requests to: Faruk İldan, M.D., Department of Neurosurgery, Çukurova University School of Medicine, Balcalı-Adana, 01330 Turkey. email: fildan@pamuk.cu.edu.tr.