British Journal of Anaesthesia **95 (5)**: 692–5 (2005)
doi:10.1093/bja/aei236 Advance Access publication September 9, 2005

BJA

Landmarks of the sacral hiatus for caudal epidural block: an anatomical study

N. Senoglu[1]*, M. Senoglu[2], H. Oksuz[1], Y. Gumusalan[3], K. Z. Yuksel[2], B. Zencirci[1], M. Ezberci[1] and E. Kızılkanat[4]

Departments of [1]Anesthesiology, [2]Neurosurgery and [3]Anatomy, KSU Medical School, 46050 Kahramanmaras, Turkey. [4]Anatomy CU Medical School, 01330 Balcali, Adana-Turkey

**Corresponding author: Kahramanmaras Sutcuimam Universitesi, Tip Fakültesi Anesteziyoloji Anabilim Dali, 46050 Kahramanmaras, Turkey. E-mail: nimetsenoglu@hotmail.com*

Background. This study determined the landmarks for caudal epidural block (CEB) after morphometric measurements of the sacral hiatus on dry sacral bones. Anatomical features of the sacral hiatus of clinical importance during CEB, along with distances and angles of use in detecting the apex, were measured. This provides detailed knowledge of the anatomy of the sacral hiatus and practical landmarks.

Methods. Ninety-six dry sacral bones were used. Anatomical measurements were made with a Vernier caliper accurate to 0.1 mm.

Results. Two sacral bones were excluded since they had total posterior closure defect. Agenesis of the sacral hiatus was detected in six sacral bones. As the posterior superior iliac spines impose on the superolateral sacral crests of the sacrum, the latter were accepted as forming the base of a triangle. The distance between the two superolateral sacral crests and the distances between the sacral apex and the right and left superolateral sacral crest were 66.5 (SD 53.5), 67.1 (10.0) and 67.5 (9.5) mm respectively, on average.

Conclusion. The triangle formed between the apex of the sacral hiatus and the superolateral sacral crests was found to have the features of an equilateral triangle. The sacrum and sacral hiatus are variable anatomical structures. However, the equilateral triangle located between the apex of the sacral hiatus and superolateral sacral crests will certainly be of use in determining the location of the sacral hiatus during CEB.

Br J Anaesth 2005; **95**: 692–5

Keywords: caudal epidural block; sacrum, sacral apex; sacrum, sacral hiatus

Accepted for publication: August 1, 2005

Caudal epidural block (CEB) involves injection of a drug into the epidural space through the sacral hiatus to provide analgesia and anaesthesia in various clinical settings.[1] The sacrum articulates with the fifth lumbar vertebra above and the coccyx below. The remnants of the inferior articular process elongate downwards on both sides of the sacral hiatus. These two bony processes are called the sacral cornua (horns) and define important clinical landmarks during CEB.[2] The sacral hiatus is located at the distal (caudal) part of the sacrum and its lateral margins are formed by the two sacral cornua. The sacral hiatus is shaped by incomplete midline fusion of the posterior elements of the distal portion of the fifth or sometimes the fourth sacral vertebra. This inverted U-shaped space is covered by the posterior aspect of the sacrococcygeal membrane and is an important landmark in CEB.[2 3] The hiatus is covered only by skin, a subcutaneous fatty layer and the sacrococcygeal membrane.[4] The distalmost portion of the dural sac and the sacral hiatus usually terminate between levels S1 and S3.

Even though CEB has a wide range of clinical applications, it is sometimes hard to determine the anatomical location of the sacral hiatus and the caudal epidural space, especially in adults. The determination of the landmarks by the clinician enables the sacral hiatus to be ascertained and may increase the success rate of CEB.

The main goal of this study was to identify additional anatomical landmarks in cases where the sacral cornua could not be identified and to measure proportions that may enhance the location of the apex of the sacral hiatus, and hence to find a practical solution for CEB. We determined measurements that may be used during CEB procedures and the anatomical borders of the sacral hiatus on dry sacral bones.

© The Board of Management and Trustees of the British Journal of Anaesthesia 2005. All rights reserved. For Permissions, please e-mail: journals.permissions@oxfordjournals.org

Methods

Ninety-six complete and undamaged adult Caucasian, dry, sacral bones obtained from four medical schools (Ankara, Cukurova, Gaziantep and Sutcu Imam) were used. The material was of undetermined gender and age. Anatomical measurements were performed on these specimens by an anatomist and a neurosurgeon using a Vernier caliper accurate to 0.1 mm. Since the posterior superior iliac spines, which are readily palpable on the body surface of a patient, impose on the superolateral sacral crests of the sacrum, and our measurements were carried out on dry sacral bones, the latter points were used as landmarks in the measurements. As the dural sac terminates around the level of S2, the distances from the apex and base of the sacral hiatus to the level of the S2 foramina were also measured.

Eleven direct morphometric measurements of importance for CEB, relating to the sacral vertebra and hiatus, were obtained (Fig. 1).

Statistical analysis

Data were expressed as mean (SD), median and range. Analyses were performed using SPSS software, version 9.0 for Windows (SPSS, Chicago, IL, USA).

Results

Total posterior closure was found in two sacrums, which were excluded from the study. Agenesis of the hiatus was detected in six (6.25%) sacrums. The average length of the sacral hiatus was 32.1 (9.9) mm (range 12–53 mm). The length of the sacral hiatus was mostly between 20 and 40 mm (Table 1). The average distance between the two superolateral sacral crests (the base of the triangle) was 66.5 (53.5) mm (range 51–79.5 mm). The distance between the right superolateral sacral crest and the sacral apex was 67.1 (10.0) mm (range 42.1–89 mm). The distance between the left superolateral sacral crest and the sacral apex was 67.5 (9.5) mm (range 46–88.1 mm). Despite these mean values, it is more important to know that the distances from the right and left sacral crests to the hiatus were similar in each sacrum. The angle between the lines formed by the base of the triangle and the sacral hiatus was 61.9 (4.8)° (range 50–70°) on the right and 61.2 (4.8)° (range 50–70°) on the left. The anatomical measurements are given in Table 2.

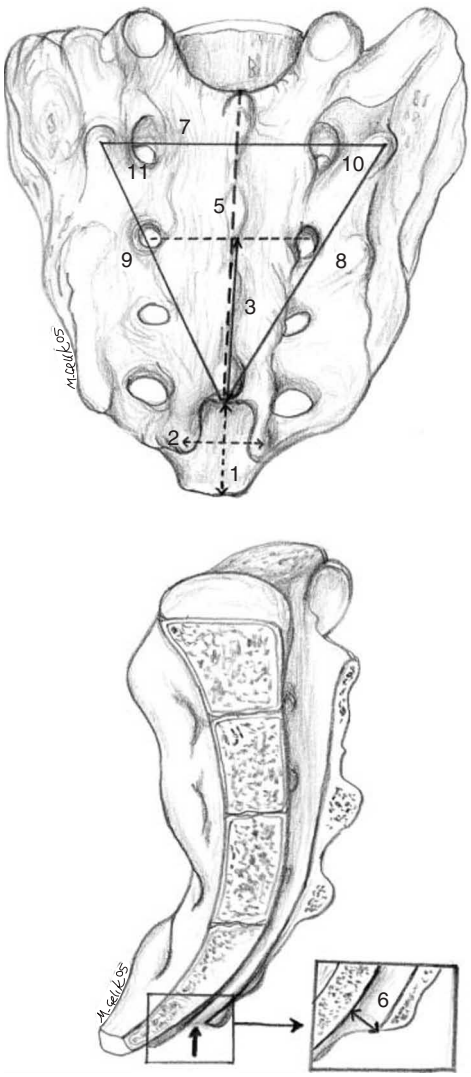

Fig 1 The measured parameters. (1) Height of sacral hiatus; (2) width of sacral hiatus at the level of sacral cornua; (3) distance from sacral apex to the level of S2 foramina; (4=1+3) distance from the base of sacral hiatus to the level of S2 foramina; (5) distance between the upper border of S1 and sacral apex; (6) depth of sacral hiatus at the level of its apex; (7) distance between the two superolateral sacral crests (the base of the triangle); (8) distance between right superolateral sacral crest and sacral apex; (9) distance between left superolateral sacral crest and sacral apex; (10) angle between the lines formed by the seventh and eighth parameters; and (11) angle between the lines formed by the seventh and ninth parameters.

Table 1 Length of the sacral hiatus

	Length of sacral hiatus				
	10–20 mm	**20–30 mm**	**30–40 mm**	**40–50 mm**	**>50 mm**
Number (%) of specimens	4 (4.4)	32 (35.6)	33 (36.7)	18 (20)	3 (3.3)

Discussion

The most frequently used technique to identify the caudal epidural space is based on feeling the 'pop' on penetrating the sacrococcygeal membrane, after the determination of the sacral hiatus by palpating the sacral cornua.[1 5] A failure rate of 25% has been reported by some investigators.[5 6] Stitz and Sommer[7] reported a success rate, without fluoroscopy, of 74%. White and colleagues[8] reported a failure rate of 25% in caudal epidural steroid injection.

Identification of the caudal epidural space is not always possible even for experienced clinicians, and anatomical variation may be an influence. The apex of the sacral hiatus is an important bony landmark in the success of CEB but it

Table 2 Results of the anatomical measurements

Measurement parameter	Mean	SD	Minimum	Maximum	Median
1 (mm)	32.09	9.92	12	53	31.50
2 (mm)	17.47	3.23	7	28	17.55
3 (mm)	35.37	10.36	11	62	36.00
4 (mm)	65.25	9.39	39	85	68.00
5 (mm)	68.74	13.16	37	96	69.50
6 (mm)	4.46	1.33	1	7	4.00
7 (mm)	66.51	53.52	51	79.5	66.50
8 (mm)	67.10	9.95	42.1	89	68.00
9 (mm)	67.53	9.48	46	88.1	68.00
10 (degrees)	61.89	4.81	50	70	60.00
11 (degrees)	61.22	4.79	50	70	60.00

may be hard to palpate, particularly in obese patients. Hence other prominent anatomical landmarks may be of use, such as the triangle formed between the posterior superior iliac spines and the apex of sacral hiatus. Our measurements show this to be an equilateral triangle. This practical guide will lead to the detection of sacral hiatus easily and increase the success rate of CEB.

Sekiguchi and colleagues[4] stated that the diameter of sacral canal was less than 2 mm in 1% of sacral bones, hence impeding the use of 22 G needles for CEB. If the sacral hiatus cannot be identified accurately it will be difficult to pass the needle into the sacral canal. A bony septum in the sacral hiatus, hiatal agenesis or complete agenesis (spina bifida) caused failure of CEB in 7% of cases.[4] It has been reported by some investigators that the sagittal (anteroposterior) diameter of the sacral canal at the apex of the hiatus was less than 2 mm in 5% of cases.[2] In our series of 96 sacral bones, this diameter was 2 mm or less in only six (6.25%). In the study of Sekiguchi and colleagues, hiatal agenesis was observed in four out of 92 sacrums (4%); however, this ratio was given as 7.7% in some other reports.[2] From our study, anatomical factors may an important factor in up to 12.5% (hiatal agenesis, 6.25%; depth of caudal canal less than 2 mm at the level of hiatal apex, 6.25%).

Sekiguchi and colleagues found the distance between the sacral cornua [10.2 (0.35) (2.2–18.4) mm] greater than, and the depth of sacral hiatus [6.0 (1.9) (1.9–11.4) mm] slightly smaller than those measured in our study [17.47 (3.23) (7–28) and 4.46 (1.33) (1–7) mm respectively]. These results were attributed to racial diversity. In addition to the measurements and morphological typing, we measured the angles between the margins of the triangle formed by the two lateral sacral crests and the sacral hiatus. We think that the equilateral features of this triangle will probably be a practical guide to the location of the apex of sacral hiatus during CEB.

The most frequently encountered problem in CEB is the failure in needle placement. Chen and colleagues stressed that the use of ultrasonography to guide needle placement during CEB would increase the success rate by 100%.[1] However, using ultrasonography or fluoroscopy is not always possible due to time, cost-effectiveness and personnel availability. Nevertheless, fluoroscopy is currently the gold standard in CEB[7 9 10] for determining correct placement of the needle, decreasing the risks of subarachnoid puncture, and intrathecal or intravascular injection. The sacral cornua, which are used in localizing the hiatus, may not always be palpable. When fluoroscopy is contraindicated or cannot be applied, knowing the anatomical relationships of the sacral hiatus will facilitate the procedure.[7]

An important point in CEB is awareness of the distance between the sacral hiatus and dural sac anatomically in relation to the risk of dural puncture. The dimensions of the sacral hiatus may vary, with its apex usually slightly above the distal third of S4, and the distance between the tip of dural sac and hiatal apex around 4.5 cm.[2] In our study, we used the level of S2 (the dural sac usually terminates at S2 in adults). The distance between the S2 foramen and the apex of the sacral hiatus was 35.4 (10.4) mm on average (range 11–62 mm) and the distance to the base of the sacral hiatus was 65.3 (9.4) mm (range 39–85 mm). We believe, in the light of these data, that the needle should be advanced only a few millimetres after penetrating the sacrococcygeal membrane in adults, in order to reduce the frequency of dural puncture and other possible complications. However, total spina bifida and detection of the dura mater just beneath the hiatus have been reported in 1% of cases.[2] A total posterior closure defect was observed in two of our sacral bones (total spina bifida 2.08%).

In conclusion, there is variability in the anatomical structure of the sacrum, especially the sacral hiatus. However, we believe that the equilateral nature of the triangle formed between the two posterior superior iliac spines and the apex of the sacral hiatus will be of practical benefit to the clinician in determining the location of the sacral hiatus during CEB. Further clinical trials are required to compare the existing techniques and our anatomical description to provide more data to support the results of this study.

Acknowledgements

We thank Mustafa Celik for his descriptive drawings and Professors Alaittin Elhan and Ibrahim Tekdemir of Ankara University Medical School for giving us the opportunity to perform this study on their collections of sacral bones.

References

1 Chen PC, Tang SFT, Hsu TC, *et al*. Ultrasound guidance in caudal epidural needle placement. *Anesthesiology* 2004; **101**: 181–4

2 Waldman SD. Caudal epidural nerve block: prone position. In: *Atlas of Interventional Pain Management*, 2nd edn. Philadelphia: Saunders, 2004; 380–92

3 Soames RW. Skeletal system. In: Williams PL, Bannister LH, Berry MM, *et al*., eds. *Gray's Anatomy*, 38th edn. Edinburgh: Churchill Livingstone, 1995; 528–31

4 Sekiguchi M, Yabuki S, Satoh K, Kikuchi S. An anatomic study of the sacral hiatus: a basis for successful caudal epidural block. *Clin J Pain* 2004; **20**: 51–4

5 Tsui BC, Tarkkila P, Gupta S, Kearney R. Confirmation of caudal needle placement using nerve stimulation. *Anesthesiology* 1999; **91**: 374–8

6 Lewis MPN, Thomas P, Wilson LF, Mulholland RC. The 'whoosh' test: a clinical test to confirm correct needle placement in caudal epidural injections. *Anaesthesia* 1992; **47**: 57–8

7 Stitz MY, Sommer HM. Accuracy of blind versus fluoroscopically guided caudal epidural injection. *Spine* 1999; **24**: 1371–6

8 White AH, Derby R, Wynne G. Epidural injections for the treatment of low back pain. *Spine* 1980; **5**: 78–86

9 Weinstein SM, Herring SA, Derby R. Contemporary concepts in spine care: epidural steroid injection. *Spine* 1995; **20**: 1842–6

10 Spaccarelli KC. Lumbar and epidural corticosteroid injections. *Mayo Clin Proc* 1996; **71**: 169–78