Tropical Medicine and International Health doi:10.1111/tmi.12698

VOLUME 21 NO 6 PP 783–791 JUNE 2016

Leishmaniasis in Turkey: first clinical isolation of *Leishmania major* from 18 autochthonous cases of cutaneous leishmaniasis in four geographical regions

Ahmet Özbilgin[1], Gülnaz Çulha[2], Soner Uzun[3], Mehmet Harman[4], Suhan Günaştı Topal[5], Fulya Okudan[6], Fadile Zeyrek[7], Cumhur Gündüz[8], İpek Östan[9], Mehmet Karakuş[10], Seray Töz[10], Özgür Kurt[11], Işın Akyar[11], Ayşegül Erat[3], Dilek Güngör[5], Çağla Kayabaşı[8], İbrahim Çavuş[1], Patrick Bastien[12], Francine Pratlong[12], Tanıl Kocagöz[11] and Yusuf Özbel[10]

1 *Department of Parasitology, Faculty of Medicine, Celal Bayar University, Manisa, Turkey*
2 *Department of Parasitology, Faculty of Medicine, Mustafa Kemal University, Hatay, Turkey*
3 *Department of Dermatology, Faculty of Medicine, Akdeniz University, Antalya, Turkey*
4 *Department of Dermatology, Faculty of Medicine, Dicle University, Diyarbakır, Turkey*
5 *Department of Dermatology, Faculty of Medicine, Çukurova University, Adana, Turkey*
6 *Clinic of Dermatology, Atatürk State Hospital, Antalya, Turkey*
7 *Department of Microbiology, Faculty of Medicine, Harran University, Şanlıurfa, Turkey*
8 *Department of Medical Biology, Faculty of Medicine, Ege University, İzmir, Turkey*
9 *Vocational School of Health Sciences, Celal Bayar University, Manisa, Turkey*
10 *Department of Parasitology, Faculty of Medicine, Ege University, İzmir, Turkey*
11 *Department of Medical Microbiology, Faculty of Medicine, Acıbadem University, İstanbul, Turkey*
12 *National Reference Center for Leishmaniases, Montpellier University Hospital, Montpellier, France*

Abstract

OBJECTIVE To report isolation of *Leishmania major* strains obtained from 18 Turkish autochthonous cutaneous leishmaniasis (CL) patients infected with *L. major* between 2011 and 2014.
METHODS Initial diagnosis relied on microscopy and culture in enriched medium, prepared by adding specific amounts of liver extract, protein and lipid sources to NNN medium. Promastigotes were then transferred to RPMI medium including 10% of foetal calf serum for mass culture. Species-specific real-time PCR targeting ITS1 region of *Leishmania* spp. was performed using both lesion aspiration samples and cultured promastigotes. Two of 18 isolates were identified by isoenzyme analysis in the Leishmaniasis Reference Center in Montpellier, France. Each isolate was inoculated into the footpads of six mice to observe the pathogenicity of *L. major*. Developing lesions were observed, and the thickening of footpads was measured weekly.
RESULTS Melting curve analyses of 18 isolates showed a peak concordant with *L. major*, and two of them were confirmed by isoenzyme analyses as *L. major* zymodeme MON103. In the mouse model, acute lesions seen on day 21 were accepted as an indication of heavy infection. Severe impairments were observed on all mouse footpads over 3 weeks, which even progressed to extremity amputation.
CONCLUSION Cutaneous leishmaniasis-causing *L. major* was recently identified in Adana province in southern Turkey, with PCR. Our study shows that such CL cases are not limited to Adana but currently present from western to Southeastern Anatolia, and along the Mediterranean coast. The role of small mammals, the main reservoirs of *L. major* in Anatolia, needs to be elucidated, as do the underlying factors that cause severe clinical manifestations in *L. major* infections in Turkey, contrary to the infections in neighbouring countries.

keywords leishmaniasis, *Leishmania major*, ITS1 RT-PCR, enriched NNN medium, mouse model, Turkey

Introduction

Leishmaniasis is a common vector-borne infection worldwide, affecting 12 million people in 98 countries or territories, with more than 350 million people at risk [1]. The causative agents are *Leishmania* species, flagellate protozoa, that live inside the macrophages in humans and are transmitted by sand flies – *Phlebotomus* spp. in

© 2016 John Wiley & Sons Ltd

the Old World and *Lutzomyia* spp. in the New World [2, 3]. Dogs and some rodents such as *Rhombomys opimus* may act as reservoir hosts for *Leishmania* species in nature [4]. This is also seen in many countries around the Mediterranean Basin, including Turkey, where cutaneous and visceral infections are documented. The main clinical manifestations of leishmaniasis are cutaneous (CL), visceral (VL) and mucocutaneous (MCL) infections [1, 2]. The causative agents of VL and CL in Turkey are *Leishmania infantum,* and *L. tropica* and *L. infantum*, respectively [5, 6].

Cutaneous leishmaniasis (CL) is a parasitic dermal infection that involves the epidermis and sometimes the mucosal tissue, and spontaneously heals with a scar on the infected area. Leading causative agents of CL in the Old World include *L. tropica*, *L. major*, *L. aethiopica* and *L. infantum*. CL is a common infection in Turkey and its eastern neighbours, such as Iran, Iraq and Syria [4, 5]. Iran is reported as one of the six countries in the world where almost two-thirds of global CL cases occur [3]. In Iraq and more recently in Syria, CL incidence has risen dramatically after the civil wars [3, 7, 8].

Turkey is located on the crossroads between Europe, Asia and Africa in a subtropical climate zone. CL has been a significant public health problem and the most important notifiable vector-borne disease in Turkey (Figure 1). A self-healing anthroponotic form of CL is endemic in the Southeastern Anatolia and Mediterranean Regions and has also been reported from the Central Anatolia and Ege Regions [5, 9]. Between 1988 and 2010, a total of 50 381 CL cases were notified in Turkey, more than half of which were from Southeastern Anatolia, mainly Şanlıurfa province [6, 10]. These cases were thought to be caused predominantly by *L. tropica*; however, some CL cases are thought to be caused by *L. infantum* in the eastern Mediterranean part of Turkey [5, 11]. Recently, *L. major* and *L. donovani* were identified by molecular methods using clinical samples of patients with CL from Adana [12] and Şanlıurfa [6] provinces in the eastern part of the country.

Phlebotomus papatasi and *P. sergenti* are well-known specific vectors for *L. major* and *L. tropica* in nature, respectively, with a widespread distribution in the Old World [13, 14]. *Phlebotomus papatasi* is highly anthropophilic and abundant in leishmaniasis-endemic areas in Turkey, according to sand fly surveys [5, 15–17].

Identification of *Leishmania* species is clinically important as *L. major* may cause severe, single or multiple, nodular cutaneous lesions involving the regional lymph nodes and accompanied by secondary bacterial or fungal infections in humans [6, 18]. Indeed, recent reports of genetic exchange between *Leishmania* species which created hybrid *Leishmania* isolates also indicate the necessity of species identification for effective planning of diagnosis and treatment [19]. This is not possible by routine diagnosis with microscopic examination or culture, but with molecular methods such as PCR followed by DNA sequencing or RFLP [20].

In this study, a total of 18 autochthonous CL cases from different regions of Turkey due to *L. major*, collected between 2011 and 2014, are presented. These are the first isolates obtained from the clinical samples of CL cases due to *L. major* in Turkey. We also aimed to report the isolation of *L. major* strains from patients with CL using a new, enriched medium, and to establish a mouse model to identify the pathogenic effects of the isolates.

Materials and methods

Patients and sampling procedure

The *Leishmania* isolates included in the study were obtained from the patients initially admitted to the Dermatology Clinics of the hospitals in different provinces, where they were suspected clinically as CL, and then referred to either Microbiology or Parasitology Laboratories of their hospitals for sample collection and certain diagnosis. After application of molecular techniques, isolates identified as *L. major* were included in the study (Table 1, Figure 2).

For sample collection, the surrounding intact skin of the patients was cleaned with 70% ethanol. Then, 0.2–0.5 ml saline solution was injected in the margin between the lesion and intact skin, and aspiration material was drawn and first inoculated into the enriched medium (EM), described below. The culture tubes were kept at 24 °C and checked regularly for the presence of promastigotes every other day for 1 month. After initial reproduction of the promastigotes, they were transferred to RPMI-1640 medium containing 10% of foetal calf serum (FCS), 200 U/ml penicillin and 0.2 mg/ml streptomycin for mass production. When the medium volume in the flasks reached 10 ml, promastigotes were collected by centrifugation and used for trials after washing five times [21]. All isolates were also cryopreserved in liquid nitrogen at −196 °C. Two isolates (MHOM/TR/2012/CBU18; MHOM/TR/2011/MK32) were sent to the National Reference Center for Leishmaniases, Montpellier, France, for isoenzyme analyses.

At least two smears were also prepared from each patient. One was stained with Giemsa after fixation in methyl alcohol and examined under a light microscope at ×1000 magnification for the presence of *Leishmania*

© 2016 John Wiley & Sons Ltd

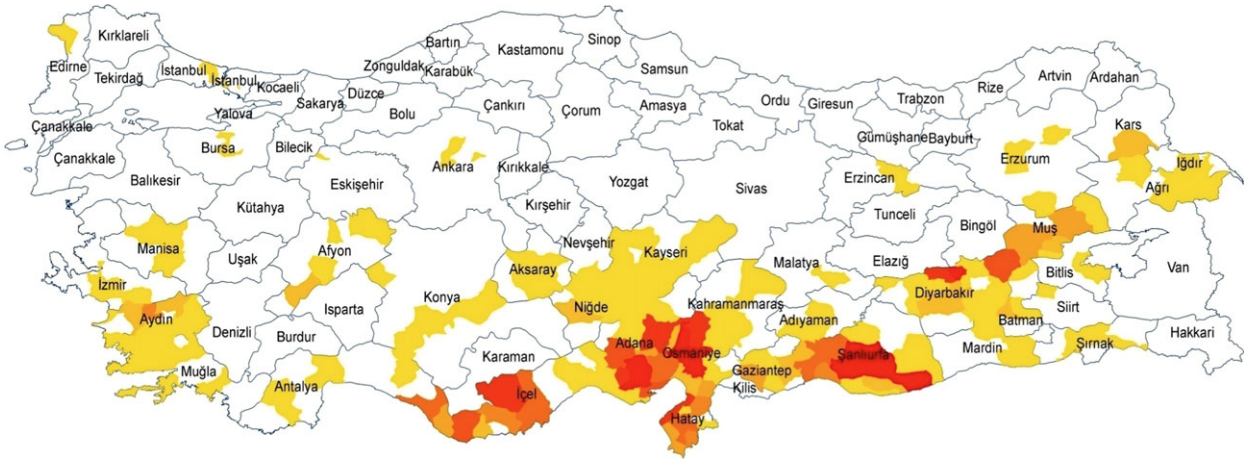

Figure 1 The prevalence of cutaneous leishmaniasis cases in Turkey between 2007 and 2009 (Courtesy by M. Kirami Ölgen).

amastigotes, while the other was kept at −20 °C for further molecular analysis.

Preparation of the enriched medium

The enriched medium (EM) was developed during the trials to cultivate *Leishmania* isolates that were not successfully cultivated with NNN medium, through modifications on the conventional medium formula. The solid phase of regular NNN medium was enriched with liver and yeast extracts, beef infusion and fresh blood. The final mixture was immediately distributed to sterile tubes at 4 ml, and the tubes were kept at room temperature until becoming solid and then transferred to +4 °C. The liquid phase of the medium consists of 1 ml of RPMI-1640 medium containing 15% FCS [22].

Molecular analysis

For DNA isolation and the PCR assay, genomic DNA was extracted from isolates and non-stained smears using a 'High Pure PCR Template Preparation Kit' (Roche Diagnostics) according to manufacturer's instructions. All DNA samples were kept at −20 °C until use.

Real-time ITS1-PCR was performed using Old World species-specific primers and probes. All procedure was carried out as described in Ozensoy Toz *et al.* [23]. Melting curves were analysed using channel 2 and 3. Four WHO reference strains were used as controls: *L. infantum/chagasi* (MHOM/XX/99/LRC-L774), *L. donovani* (MHOM/IN/80/DD8), *L. tropica* (MHOM/IL/90/LRC-L590 and MHOM/IL/96/LRC-L691) and *L. major* (MHOM/IL/2000/LRC-L779).

To observe the *in vivo* clinical manifestations of *L. major* infections and compare them with the control group, two new *Leishmania* isolates (MHOM/TR/2012/CBU18; MHOM/TR/2011/MK32) were used in an animal model. Two study groups and one control group were established; each consisted of six mice (20–25 g/5- to 7-week-old female BALB/c) [24]. Two isolates were removed from liquid nitrogen and after confirming their viability under the microscope; promastigotes were inoculated into the left footpads of the mice at 100 µl (1×10^8 promastigotes/ml). Using a digital micrometre, the sizes of any developing lesions on the footpads of each mouse were measured weekly for 3 months; any redness and/or swelling at the infection site after the 2nd week of inoculation was also documented. At the end of 3 months, lesion samples were obtained through aspiration of injected saline solution at the border of the lesion and intact skin. This aspiration material was immediately inoculated into NNN medium and also used for Giemsa-stained smear preparations to identify amastigotes.

Ethical approval

This study aimed to present all CL cases due to *L. major* in Turkey between 2011 and 2014; therefore, the cases were selected from different studies, all of which had already been approved by ethical committees as follows: (i) Ege University Local Ethical Committee for Laboratory Animals (No: 2011-006-28.01.2011); (ii) Celal Bayar University Local Ethical Committee for Laboratory Animals (No: 77.637.435-73-11.12.2013); (iii) Celal Bayar University Local Ethical Committee for Research Studies on Humans (No: 003-08.02.2011; No: 16-17.01.2013; No: 17-17.01.2013).

© 2016 John Wiley & Sons Ltd

Table 1 The data related to patients, their lesions and isolates

Patient No	Sex	Region	Province/town	WHO code of isolates	No. of lesions	Site of lesion(s)
1	M	M	Antalya/Serik	MHOM/TR/2013/CBUANT009	3	Hand, arm, finger
2	M	M	Antalya/Alanya/	MHOM/TR/2013/CBUANT012	1	Ankle
3	F	M	Antalya/Kepez	MHOM/TR/2013/CBUANT014	1	Face
4	F	M	Antalya/Gazipaşa	MHOM/TR/2013/CBUALA016	1	Face
5	M	M	Antalya/Alanya	MHOM/TR/2013/CBUALA17	1	Hand
6	F	M	Antalya/Alanya	MHOM/TR/2013/CBUALA005	2	Face, shoulder
7	M	M	Adana/Yüreğir	MHOM/TR/2013/CBUADN019	1	Arm
8	F	M	Adana/Sarıçam	MHOM/TR/2013/CBUADN021	2	Wrist
9	F	M	Hatay/Reyhanlı	MHOM/TR/2011/MK32* (*L. major* MON103)	2	Wrist
10	M	SE	Mardin/Kızıltepe	MHOM/TR/2013/CBUDYR19	4	Leg
11	M	SE	Mardin/Kızıltepe	MHOM/TR/2013/CBUDYR45	4	Legs, feet
12	F	SE	Diyarbakir/Dicle	MHOM/TR/2013/CBUDYR16	2	Leg
13	M	SE	Diyarbakir/Silvan	MHOM/TR/2013/CBUDYR27	1	Face
14	M	SE	Diyarbakir/Hani	MHOM/TR/2013/CBUDYR43	1	Hand
15	M	SE	Sanliurfa/Ceylanpınar	MHOM/TR/2014/CBUDYR98	1	Foot
16	M	EA	Bitlis/Hizan	MHOM/TR/2012/CBU18* (*L. major* MON103)	1	Face
17	F	E	Manisa/Merkez	MHOM/TR/2014/CBU33	1	Face
18	M	E	Burdur/Mamak	MHOM/TR/2013/CBUANT013	1	Face

Regions: M, Mediterranean; SE, Southeastern Anatolia; EA, East Anatolia; E, Ege.
*Isolates identified by isoenzyme analysis.

Results

Basic information about the patients and their lesions is shown in Table 1. Men outnumbered women [11 (61.11%) *vs.* 7 (38.89%)]. Eleven of the 18 patients had only one lesion, mostly on the face, and two had four lesions on their body (Table 1). Interestingly, geographical distribution of the patients was not limited to CL-endemic Southeastern Anatolia; instead, patients were from provinces from four different geographical regions: Eastern Anatolia, Southeastern Anatolia, Ege Region and Mediterranean Region (Figure 2). The lesions were larger than the lesions observed with *L. tropica*. They were also ulcerated, surrounded by large redness and sometimes infected secondarily with bacteria (Figure 3). All patients were local Turkish villagers, with no previous history of travel abroad, or any history of travel out of their provinces in the last 12 months. They were either farmers or stockbreeders, with low incomes (<700 US Dollars/month). All were diagnosed with CL between January and March (8 in January, 3 in February and 7 in March).

Initial microscopic examinations of Giemsa-stained smears and cultures of all samples identified *Leishmania* spp. Further assessments with ITS1 RT-PCR of both clinical samples and culture material revealed melting curves concordant with *L. major*. Moreover, isoenzyme analyses of two selected cultivated samples identified the parasite as *L. major* zymodeme MON103.

In vivo assessments revealed that the acute lesions had developed on the footpads of mice just after the 3rd routine control, on the 21st day of inoculation, indicating an early and heavy infection. These lesions progressed within 3 weeks; their sizes increased day by day and led to severe impairments on the skins of all mice, except controls, even to the total amputation of the extremity (Figure 4).

Discussion

Cutaneous leishmaniasis caused by several *Leishmania* species has long been known in subtropical Anatolia; its public health importance has been on the rise due to the detection of different *Leishmania* species as causative agents in Turkey. There has been a marked increase in CL incidence in recent years in Turkey, both in terms of clinical cases and the foci of infection, which may be related in part to the intense and continuing influx of Syrian refugees to Turkey [6, 12], raising concern for possible future epidemics.

Cutaneous leishmaniasis due to *L. major,* known as zoonotic cutaneous leishmaniasis (ZCL), is still an increasing public health problem in the Middle East and northern African countries [25–27]. It is transmitted by a well-known and widespread proven vector species, *P. papatasi*, and the disease is present at least in 15 of 30 provinces of Iran, existing with three genetic clusters of

© 2016 John Wiley & Sons Ltd



Figure 2 The locations of 18 autochthonous cases caused by *Leishmania major*.

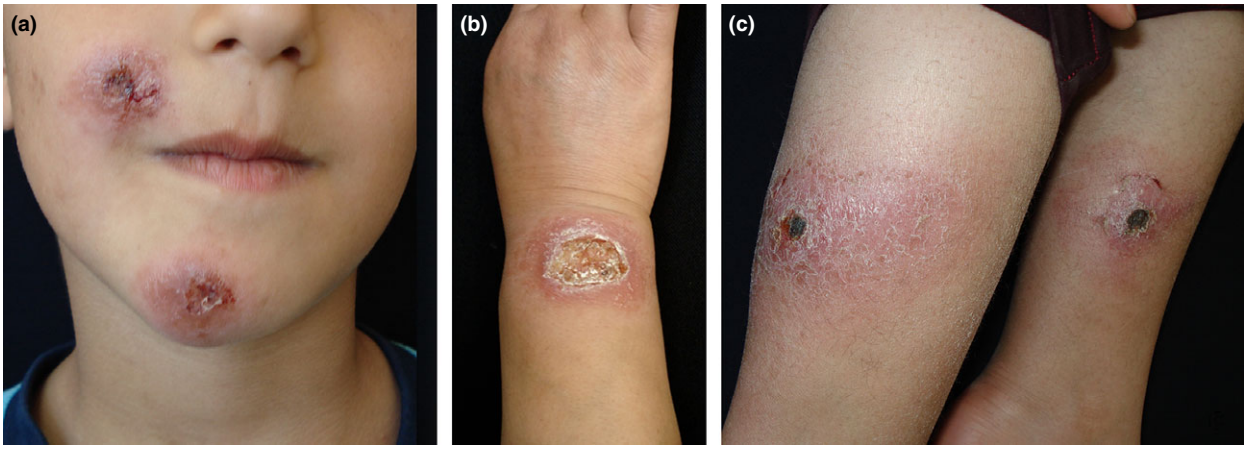

Figure 3 Lesions of cutaneous leishmaniasis on the face (a), wrist (b) and on the legs (c) of the patients.

L. major [28]. It is more common than the anthroponotic form, and the rodents such as *R. opimus* and *Meriones libycus erythrosus* are indicated as the leading reservoirs of *L. major* in Iran [29, 30]. Indeed, unusual clinical manifestations of CL due to *L. major* have also been reported in Iran, such as disseminated CL [31] and mucosal leishmaniasis [32]. It is mainly transmitted by *Ph. papatasi* while the fat sand rat, *Psammomys obesus,* is its reservoir in most foci between Morocco in the west and Syria and Saudi Arabia in the east [26, 33, 34]. To date, there is no information or previous study about the local reservoirs of *L. major* in Turkey. Therefore, further studies especially focused on small rodents are now urgently necessary in Turkey.

In the present study, 18 CL cases caused by *L. major* were determined from nine provinces of Turkey in Mediterranean (9), Southeastern Anatolia (6), East Anatolia (1) and Ege (2) Regions. This is the first study performed by molecular and isoenzymatic tools using clinical isolates obtained from autochthonous CL patients from different provinces. Our results confirm previous findings of the presence of *L. major* in Turkey. They also show its widespread distribution from the Ege Region to the Southeast along the Mediterranean coast. The rising incidence of *L. major* infections is due to many factors. One is the recent arrival of more than 2 million refugees from Syria, where CL, including *L. major* infections, was more prevalent than in Turkey [35]. Another is the effect of the predicted increase in average temperatures in Turkey, especially in summer, which may extend the survival times of the vectors [36–38]. Finally, our results point out the importance of species-specific diagnosis for CL cases that can affect the treatment regimen and control measures in endemic areas.

© 2016 John Wiley & Sons Ltd

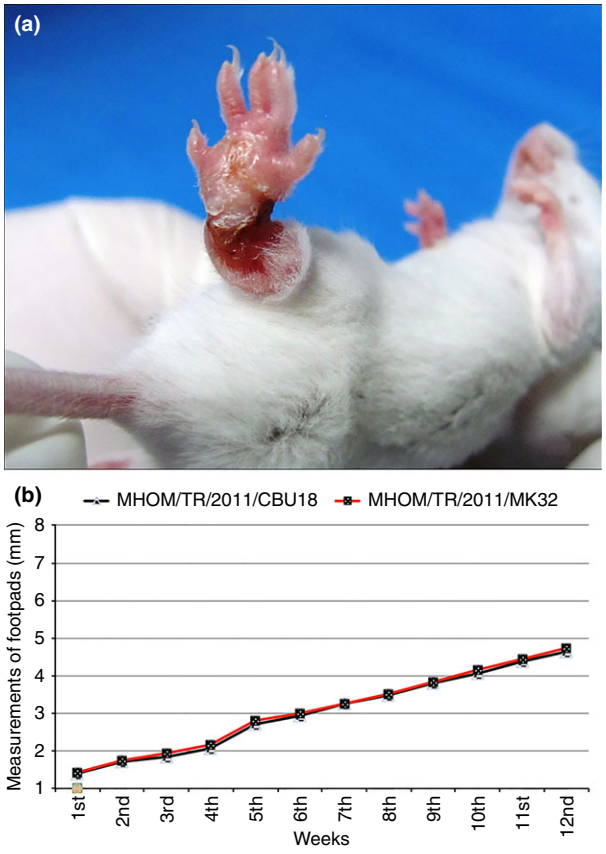

Figure 4 (a) Developed cutaneous leishmaniasis lesion on the footpad of the mice infected with *Leishmania major*; (b) The average thickening of the infected footpads of mice in 3 weeks.

We also studied the pathogenic effects of two of these *L. major* isolates in a mouse model. Skin lesions developed just after 21 days of inoculation in all mice, which indicated a severe and fast-developing infection (Figure 4). The sizes of the skin lesions enlarged constantly and ended with total loss of the extremity. This aggressive behaviour of autochthonous *L. major* isolates is opposite to the behaviour of the isolates from Iran and other Middle East countries [3]. They act rather more severely on mice than *L. tropica* isolates in Turkey as well [39]. This may be due to several factors such as the immune response of the host, genetic diversity of the parasite or the presence of natural viruses of *Leishmania* species [*Leishmania* RNA Virus (LRV)] [40]. There are no data about LRV in *Leishmania* isolates from Turkey at the moment; thus, further study of LRV will not only help understanding its pathological effects but also provide new information on *L. major* to the scientific community.

Entomological surveys have already been conducted in more than 30 provinces including the locations where *L. major* cases were detected, such as Adana, Manisa, Şanlıurfa and Hatay. The proven vector species of *L. major*, *P. papatasi,* is one of the most common sand fly species in Turkey. In entomological surveys on sand flies in Turkey, *P. papatasi* was found to be present in 16.4% and 25% of samples in Adana [41, 42]; 48% in Manisa [43]; 27.2% and 45.4% [17, 44] in Şanlıurfa and 18.8% and 28.5% [42, 45] in Hatay provinces. In view of the wide distribution of *P. papatasi* and its high population density, it would not be surprising to diagnose more ZCL cases caused by *L. major* in Turkey in the near future.

Turkey's southern and eastern neighbours have also been suffering from CL for centuries. In Iran, CL is documented from 17 of 31 provinces with an increasing annual trend over the last years, with more than 20 000 new cases reported annually. Leading species are *L. tropica* and *L. major*, which are responsible from anthroponotic and zoonotic infections, respectively [46]. Civil wars in Turkey's southern neighbours, Iraq and Syria, cause migration of many non-immune citizens to endemic regions for certain infections, or vice versa, which may result in epidemics [47]. In Iraq, CL has been endemic with *L. tropica* and *L. major* as the main causative agents. Lack of proper data prevents precise assessments of the current prevalence of the disease, just as in Syria [3]. Syria is among the 10 countries with highest CL case counts in the world, and CL has long been seen in Aleppo where it is popularly known as 'Aleppo Boil'. CL incidence has been on the rise after the 1990s; it reached 53 000 cases in 2012 and 41 000 in the first half of 2013. There are no data for 2014, but considering that many Syrians are now immigrants in neighbouring countries, CL epidemics now constitute an obvious risk for the whole region [35]. ZCL due to *L. major* has long been reported in Syria, mainly in the suburbs of the capital city, Damascus [35, 48]. One of the patients in our study group is a Turkish driver who had been working in the Refugee Camp of Syrians. He initially presented with a lesion on his left foot and reported working only in and out of the refugee camp, without any travel to Syria. This indicates the role of human movements as one of the major risks for spreading vector-borne infections. Another example was reported from Lebanon, where more than 1 million Syrian refugees are present. In an outbreak of leishmaniasis in 2013 with 1033 leishmaniasis cases, 998 were Syrian refugees (96.6%). In the first 3 months of 2014, an additional 217 cases were diagnosed, of whom 208 were Syrian refugees and almost 70% of these cases were children, aged 0–18 years [7]. Among the patients in our study, *L. major* was first

© 2016 John Wiley & Sons Ltd

identified in a patient with CL in 2011, before the arrival of Syrian refugees to Turkey. This strongly suggests that autochthonous ZCL due to *L. major* was already present in Turkey and is not related to the arrival of Syrian refugees. Indeed, none of the patients in the study group has reported any recent visit to a *Leishmania*-endemic neighbouring country.

We also report the use of an enriched culture medium for more efficient parasite isolation. Interestingly, it was noted that some of the amastigotes of *L. major* obtained from the patient samples or laboratory animals could not be transformed to promastigotes, while some others could not reproduce after transforming to promastigotes and died shortly after becoming round particles. Using NNN-EM, it was possible to amplify those *L. major* promastigotes *in vitro* successfully. We believe it is likely that many CL cases due to *L. major* were overlooked in Anatolia before our trials with enriched medium. Indeed, the recent report of the retrospective assessment of patient samples in south-eastern Turkey by molecular methods indicated the presence of *L. tropica, L. infantum* and *L. major* in autochthonous cases [12, 49, 50]. Therefore, given that molecular methods are still too expensive for routine work, the efficacy of NNN medium should be re-evaluated in the diagnoses of CL and VL and our enriched medium should be tested for its efficacy in larger populations as a new candidate.

In conclusion, *L. major* was recently reported as a causative agent of CL in Adana province, Turkey; however, our study showed that it has spread more widely, from Ege Region to Southeastern Anatolia along the Mediterranean coast. This is also the first report of clinically isolated and successfully cultivated *L. major* parasites from autochthonous CL cases in Turkey. Dermatologists working in regions with higher CL incidence should consider CL when they encounter patients with odd, aggressive skin lesions, particularly on the arms, legs, faces and even mucosa. Regarding its strategic location on the crossroads between Asia, Africa and Europe, Turkey is currently under threat of a wide range of infectious diseases and epidemics across the country. Our findings and previous surveys indicate the presence of several *Leishmania* parasites and their insect vectors in Turkey; reservoirs of leishmaniasis, especially small rodents, should be examined thoroughly across Anatolia, to assess their role in the transmission of leishmaniasis and to take measures to control it.

Acknowledgements

This project was supported by The Scientific and Technological Research Council of Turkey (TUBITAK) with the project No: 111S179 and by Research Funds of Celal Bayar University with the Projects no: CBUBAP 2013-02 / CBUBAP 2013-03. We thank Asc. Prof. M. Kirami Ölgen for preparing the map, and 'Parasite Bank' in Celal Bayar University Faculty of Medicine for keeping and supplying the isolates.

References

1. de Vries HJ, Reedijk SH, Schallig HD. Cutaneous leishmaniasis: recent developments in diagnosis and management. *Am J Clin Dermatol* 2015: **16**: 99–109.
2. Desjeux P. Leishmaniasis: current situation and new perspectives. *Comp Immunol Microbiol Infect Dis* 2004: **27**: 305–318.
3. Salam N, Al-Shaqha WM, Azzi A. Leishmaniasis in the Middle East: incidence and epidemiology. *PLoS Negl Trop Dis* 2014: **8**: e3208.
4. Ozbel Y, Ozensoy Toz S. Leishmaniosis. In: Ozcel MA (ed). *Tıbbi Parazit Hastaliklari (Medical Parasitic Diseases)*. Meta Basim Matbaacilik Hizmetleri: Izmir, 2007, pp. 197-244.
5. Ok UZ, Balcioglu IC, Taylan Ozkan A, Ozensoy S, Ozbel Y. Leishmaniasis in Turkey. *Acta Trop* 2002: **84**: 43–48.
6. Zeyrek FY, Gurses G, Uluca N *et al.* Is the agent of cutaneous leishmaniasis in Sanliurfa changing? First cases of *Leishmania major*. *Turkiye Parazitol Derg* 2014: **38**: 270–274.
7. Alawieh A, Musharrafieh U, Jaber A, Berry A, Ghosn N, Bizri AR. Revisiting leishmaniasis in the time of war: the Syrian conflict and the Lebanese outbreak. *Int J Infect Dis* 2014: **29**: 115–119.
8. Klaus S, Frankenburg S. Cutaneous leishmaniasis in the Middle East. *Clin Dermatol* 1999: **17**: 137–141.
9. Gürel MS, Yeşilova Y, Ölgen MK, Özbel Y. Cutaneous leishmaniasis in Turkey. *Turkiye Parazitol Derg* 2012: **36**: 121–129.
10. Demirel R, Erdogan S. Determination of high risk regions of cutaneous leishmaniasis in turkey using spatial analysis. *Turkiye Parazitol Derg* 2009: **33**: 8–14.
11. Alvar J, Vélez ID, Bern C *et al.* Leishmaniasis worldwide and global estimates of its incidence. *PLoS One* 2012: **7**: e35671.
12. Koltas IS, Eroglu F, Alabaz D, Uzun S. The emergence of *Leishmania major* and *Leishmania donovani* in southern Turkey. *Trans R Soc Trop Med Hyg* 2014: **108**: 154–158.
13. Boussaa S, Kahime K, Samy AM, Salem AB, Boumezzough A. Species composition of sand flies and bionomics of Phlebotomus papatasi and *P. sergenti* (Diptera: Psychodidae) in cutaneous leishmaniasis endemic foci, Morocco. *Parasit Vectors* 2016: **9**: 60.
14. Chajbullinova A, Votypka J, Sadlova J *et al.* The development of Leishmania turanica in sand flies and competition with *L. major*. *Parasit Vectors* 2012: **5**: 219.
15. Ergunay K, Kasap OE, Orsten S *et al. Phlebovirus* and *Leishmania* detection in sandflies from eastern Thrace and northern Cyprus. *Parasit Vectors* 2014: **12**: 575.

© 2016 John Wiley & Sons Ltd

16. Erisoz Kasap O, Alten B. Comparative demography of the sand fly *Phlebotomus papatasi* (Diptera: Psychodidae) at constant temperatures. *J Vector Ecol* 2007: **31**: 378–385.
17. Volf P, Özbel Y, Akkafa F, Svobodova M, Votypka J, Chang KP. Sand flies (Diptera: Phlebotominae) in Sanliurfa, Turkey: Relationship of *Phlebotomus sergenti* with the epidemic of anthroponotic cutaneous leishmaniasis. *J Med Entomol* 2007a: **39**: 12–15.
18. van Thiel PP, Leenstra T, de Vries HJ *et al.* Cutaneous leishmaniasis (*Leishmania major* infection) in Dutch troops deployed in northern Afghanistan: epidemiology, clinical aspects, and treatment. *Am J Trop Med Hyg* 2010: **83**: 1295–1300.
19. Volf P, BenkovaI I, Myskova J, Sadlova J, Campino L, Ravel C. Increased transmission potential of *Leishmania major/Leishmania infantum* hybrids. *Int J Parasitol* 2007b: **37**: 589–593.
20. Ozensoy Toz S, Nasereddin A, Ozbel Y *et al.* Leishmaniasis in Turkey: molecular characterization of *Leishmania* from human canine samples. *Trop Med Int Health* 2009: **14**: 1401–1406.
21. Garcia LS, Bruckner DA. *Sputum, Diagnostic Medical Parasitology* (2nd edn), American Society for Microbiology: Washington, 1993.
22. Ozbilgin A, Ozbel Y, Alkan MZ, Atambay M, Ozcel MA. Cultivation of *Leishmania* sp. in nutrient broth. *J Egypt Soc Parasitol* 1995: **25**: 437–441.
23. Ozensoy Toz S, Culha G, Yıldız Zeyrek F *et al.* A real-time ITS1-PCR based method in the diagnosis and species identification of *Leishmania* parasite from human and dog clinical samples in Turkey. *PLoS Negl Trop Dis* 2013: **7**: e2205 (1–8).
24. Croft SL, Yardley V. Animal models of visceral leishmaniasis. In: Zak O, Sande MA (eds). *Handbook of Animal Models of Infection*. Academic Press, London, 1999. ISBN: 978-0-12-775390-4.
25. Elfari M, Schnur LF, Strelkova MV *et al.* Genetic and biological diversity among populations of *Leishmania major* from Central Asia, the Middle East and Africa. *Microbes Infect* 2005: **7**: 93–103.
26. Gramiccia M, Gradoni L. The current status of zoonotic leishmaniases and approaches to disease control. *Int J Parasitol* 2005: **35**: 1169–1180.
27. Pratlong F, Dereure J, Ravel C, Lami P, Balard Y. Geographical distribution and epidemiological features of Old World cutaneous leishmaniasis foci, based on the isoenzyme analysis of 1048 strains. *Trop Med Int Health* 2009: **14**: 1071–1085.
28. Akhoundi M, Hajjaran H, Baghaei A, Mohebali M. Geographical distribution of leishmania species of human cutaneous leishmaniasis in Fars province, southern Iran. *Iran J Parasitol* 2013: **8**: 85–91.
29. Hajjaran H, Mohebali M, Abaei MR *et al.* Natural infection and phylogenetic classification of *Leishmania spp*. infecting *Rhombomys opimus*, a primary reservoir host of zoonotic cutaneous leishmaniasis in Northeast Iran. *Trans R Soc Trop Med Hyg* 2013a: **107**: 550–557.
30. Kassiri H, Naddaf SR, Javadian EA, Mohebali M. First report on isolation and characterization of *Leishmania major* from *Meriones hurrianae* (Rodentia: Gerbillidae) of a rural cutaneous leishmaniasis focus in south-eastern Iran. *Iran Red Crescent Med J* 2013: **15**: 789–793.
31. Hajjaran H, Mohebali M, Akhavan AA, Taheri A, Barikbin B, Soheila Nassiri S. Unusual presentation of disseminated cutaneous leishmaniasis due to *Leishmania major*: case reports of four Iranian patients. *Asian Pac J Trop Med* 2013b: **6**: 333–336.
32. Shirian S, Oryan A, Hatam GR, Daneshbod Y. Three *Leishmania* species – *L. infantum, L. major, L. tropica* – as causative agents of mucosal leishmaniasis in Iran. *Pathog Glob Health* 2013: **107**: 267–272.
33. Ajaoud M, Es-sette N, Hamdi S, El-Idrissi AL, Riyad M, Lemrani M. Detection and molecular typing of *Leishmania tropica* from *Phlebotomus sergenti* and lesions of cutaneous leishmaniasis in an emerging focus of Morocco. *Parasit Vectors* 2013: **6**: 217.
34. Mondragon-Shem K, Al-Salem WS, Kelly-Hope L *et al.* Severity of old world cutaneous leishmaniasis is influenced by previous exposure to sandfly bites in Saudi Arabia. *PLoS Negl Trop Dis* 2015: **9**: e0003449.
35. Hayani K, Dandashli A, Weisshaar E. Cutaneous leishmaniasis in Syria: clinical features, current status and the effects of the war. *Acta Derm Venereol* 2015: **95**: 62–66.
36. Sen ÖL. *A Holistic View of Climate Change and Its Impacts in Turkey*. Istanbul Policy Center, Sabanci University, Stiftung Mercator Initiative: Istanbul, Turkey, 2013. ISBN: 978-605-4348-65-7.
37. Tayanç M, Toros H. Urbanization effects on regional climate change in the case of four large cities of Turkey. *Clim Change* 1997: **35**: 501–524.
38. Tayanç M, Im U, Dogruel M, Karaca M. Climate change in Turkey for the last half century. *Clim Change* 2009: **94**: 483–502.
39. Girginkardeşler N, Balcioglu IC, Yereli K, Ozbilgin A, Ozbel Y. Cutaneous leishmaniasis infection in Balb/c mice using a *Leishmania tropica* strain isolated from Turkey. *J Parasitol* 2001: **87**: 1177–1178.
40. Ives A, Ronet C, Prevel F *et al. Leishmania* RNA virus controls the severity of mucocutaneous leishmaniasis. *Science* 2011: **331**: 775–778.
41. Atakan E, Akbaba M, Sütoluk Z, Alptekin D, Demirhindi H, Kis Uludağ S. Population density of phlebotomus (Diptera; Psychodidae; Phlebotomine) species and their relationship with cutaneous leishmaniasis in Hocalli and Iurunçlu Villages (Adana). *Turkiye Parazitol Derg* 2010: **34**: 106–111.
42. Simsek F, Alten B, Caglar SS *et al.* Distribution and altitudinal structuring of phlebotomine sand flies (Diptera: Psychodidae) in southern Anatolia, Turkey: their relation to human cutaneous Leishmaniasis. *J Vector Ecol* 2007: **32**: 269–279.
43. Balcioglu IC, Ozensoy S, Yereli K *et al.* Kala-azar cases and *Phlebotomus sp*. inside Manisa and its hinterland region between the years 1990–1995. *Turkiye Parazitol Derg* 1996: **19**: 367–373 [Turkish].

© 2016 John Wiley & Sons Ltd

44. Toprak S, Ozer N. Sandfly species in Sanliurfa province in Turkey. *Med Vet Entomol* 2005: **19**: 107–110.
45. Yaman M, Özbel Y. The sandflies (Diptera: Psychodidae) in the Turkish province of Hatay: some possible vectors of the parasites causing human cutaneous leishmaniasis. *Ann Trop Med Parasitol* 2004: **98**: 741–750.
46. Mohammadi AMA, Khamesipour A, Khatami AR *et al.* Cutaneous leishmaniasis in suspected patients referred to the center for research and training in skin diseases and leprosy, Tehran, Iran from 2008 to 2011. *Iran J Parasitol* 2013: **8**: 430–436.
47. Dawit G, Girma Z, Simenew K. A review on biology, epidemiology and public health significance of leishmaniasis. *J Bacteriol Parasitol* 2013: **4**: 2.
48. Tayeh A, Jalouk L, Cairncross S. Twenty years of cutaneous leishmaniasis in Aleppo, Syria. *Trans R Soc Trop Med Hyg* 1997: **91**: 657–659.
49. Eroglu F, Uzun S, Koltas IS. Comparison of clinical samples and methods in chronic cutaneous leishmaniasis. *Am J Trop Med Hyg* 2014: **91**: 895–900.
50. Akcali C, Culha G, Inaloz H, Savas N, Onlen Y, Savas L. Cutaneous leishmaniasis in Hatay. *J Turk Acad Dermatol* 2007: **1**: 1–5.

Corresponding Author Özgür Kurt, Department of Medical Microbiology, Faculty of Medicine, Acibadem University, Istanbul 34752, Turkey. Tel.: +90 216 500 4122; E-mail: ozgur.kurt@acibadem.edu.tr; oz1605@hotmail.com

© 2016 John Wiley & Sons Ltd